

**ANALYSIS OF HUMAN SKELETAL REMAINS
DISCOVERED BY CONSTRUCTION
ACTIVITIES,
DRAFTS GRAVEYARD, LEXINGTON COUNTY,
SOUTH CAROLINA**



CHICORA RESEARCH CONTRIBUTION 476

**ANALYSIS OF HUMAN SKELETAL REMAINS DISCOVERED
BY CONSTRUCTION ACTIVITIES, DRAFTS GRAVEYARD,
LEXINGTON COUNTY, SOUTH CAROLINA**

Prepared By:
Debi Hacker
and
Michael Trinkley, Ph.D., RPA

Prepared For:
Mr. Eddie Yandle
N.B.T. of Columbia, Inc.
117 Beaver Ridge Dr
Elgin, SC 29045

CHICORA RESEARCH CONTRIBUTION 476



Chicora Foundation, Inc.
PO Box 8664
Columbia, SC 29202-8664
803/787-6910
www.chicora.org

July 24, 2007

This report is printed on permanent paper ∞

©2007 by Chicora Foundation, Inc. All rights reserved. No part of this publication may be reproduced, stored in a retrieval system, transmitted, or transcribed in any form or by any means, electronic, mechanical, photocopying, recording, or otherwise without prior permission of Chicora Foundation, Inc. except for brief quotations used in reviews. Full credit must be given to the authors, publisher, and project sponsor.

ABSTRACT

In late June 2007 construction at a proposed development about three miles west of the City of Lexington in Lexington County, South Carolina uncovered human remains. The Lexington County Coroner and Sheriff's Department were notified in order to determine if the remains represented a forensic case. The coroner determined that the remains did not and that they were more likely evidence of a "lost" family graveyard. As a result the developer of the property, N.B.T. of Columbia, Inc. requested that Chicora Foundation become involved to determine the size of the graveyard, the number of individuals that might be present, and provide recommendations.

A previous report has provided historical documentation of the cemetery and its probable occupants. This study provides brief metric and non-metric analysis of the human skeletal remains recovered accidentally by the construction activities. No destructive analyses, such as bone chemistry or DNA studies, were conducted.

Burial 1 is of a gracile African American male over the age of 50, standing between 5 feet 8 inches and 6 feet 1 inch in height. While incomplete, the remains include both cranial and post cranial materials in good condition.

Burial 2 consists only of partial cranial remains in good, but heavily fragmented, condition. The individual is likely a female over the age of 35.

Health of the two individuals was generally good. The absence of hypoplasia in the teeth indicates that there was no significant nutritional or other health related stress during childhood. There is no indication of anemia or long lasting infections such as syphilis or tuberculosis. There is no significant arthritis evidenced in any of the recovered bones. No indication of poorly healed breaks - in fact no evidence of any ante-mortem trauma. While little

can be drawn from this sample, the Drafts family appears to be healthy for African Americans of the period.

This study also provides recommendations for metric, non-metric, and chemical studies that could be conducted should it become necessary to move any of burials. There is an unprecedented opportunity to examine lifeways, diet, disease, and health of a Midlands African American population. We explain that this is a perfect example of the dead teaching the living - providing information that is available through no other avenues of research.

TABLE OF CONTENTS

List of Figures		iv
List of Tables		iv
Introduction		1
<i>Background</i>	1	
<i>Historical Synopsis</i>	3	
<i>Excavation of the Remains</i>	5	
<i>Scattered Remains</i>	6	
Analysis of Burials 1 and 2		9
<i>Burial 1</i>	9	
<i>Burial 2</i>	14	
Conclusions and Recommendations		17
Sources Cited		19

LIST OF FIGURES

Figure

1. Portion of the State of South Carolina map showing the project area	1
2. Portion of the Barr Lake USGS topographic map showing the development area	2
3. Plan of a portion of the development showing the location of Burials 1 and 2	3
4. View of the development tract looking south	4
5. Central development area	4
6. Examples of human bone identified from the surface	6
7. Burial 1	13
8. Burial 2	15

LIST OF TABLES

Table

1. Potentially human remains from east of Dawson's Park Way	5
2. Cranial measurements for Burial 1	10
3. Sex estimation	11
4. Stature estimation	12
5. Cranial measurements for Burial 2	14

INTRODUCTION

Background

On June 20 construction crews excavating utility lines at the Dawson's Park development about 3 miles west of the City of Lexington uncovered human skeletal remains and notified the Lexington County Coroner and Sheriff's Department. During the day-long investigation by

a halt to the work until additional assessment could be performed. The coroner determined that the remains were not forensic, but rather those of a family cemetery, and requested that the developer of the property, Mr. Edward D. Yandle of N.B.T. of Columbia, Inc., oversee the additional work.

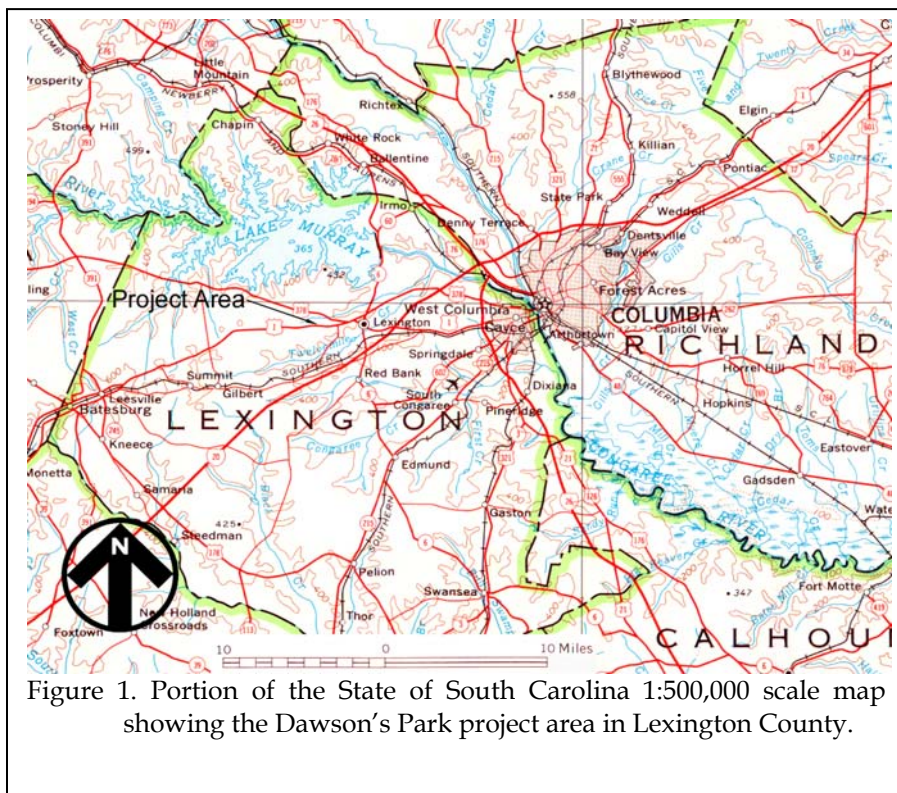


Figure 1. Portion of the State of South Carolina 1:500,000 scale map showing the Dawson's Park project area in Lexington County.

the Sheriff's Department, which included screening the spoil from the primary excavation, additional remains were found about 100 feet to the south in a second excavation. The entire development had been cleared, grubbed, utilities were laid, and streets were in the process of being constructed.

The coroner, Mr. Harry Harmon, ordered

It was at that time that Mr. Yandle requested Chicora Foundation's involvement to examine the property and provide recommendations regarding the size of the cemetery.

Our initial investigation, by Ms. Julie Poppell of the Chicora staff, was conducted on June 22. The excavations were still open and it was clear where the Sheriff's Department had been screening spoil for the recovery of remains. Arrangements were made for a more careful inspection on June 25.

On Monday, June 25 the author, Dr. Michael Trinkley, visited the site with staff members Nicole

Southerland and Julie Poppell. The two burials were identified on the east side of Dawson's Circle, on the west side of the development. Burial 1, which was more complete and had been recovered by the Sheriff's Department from spoil, was apparently between lots 156 and 157, although no evidence of the burial pit was immediately evident. Burial 2, represented by only a partial skull, had been recovered from a different

ANALYSIS OF HUMAN SKELETAL REMAINS DISCOVERED BY CONSTRUCTION ACTIVITIES

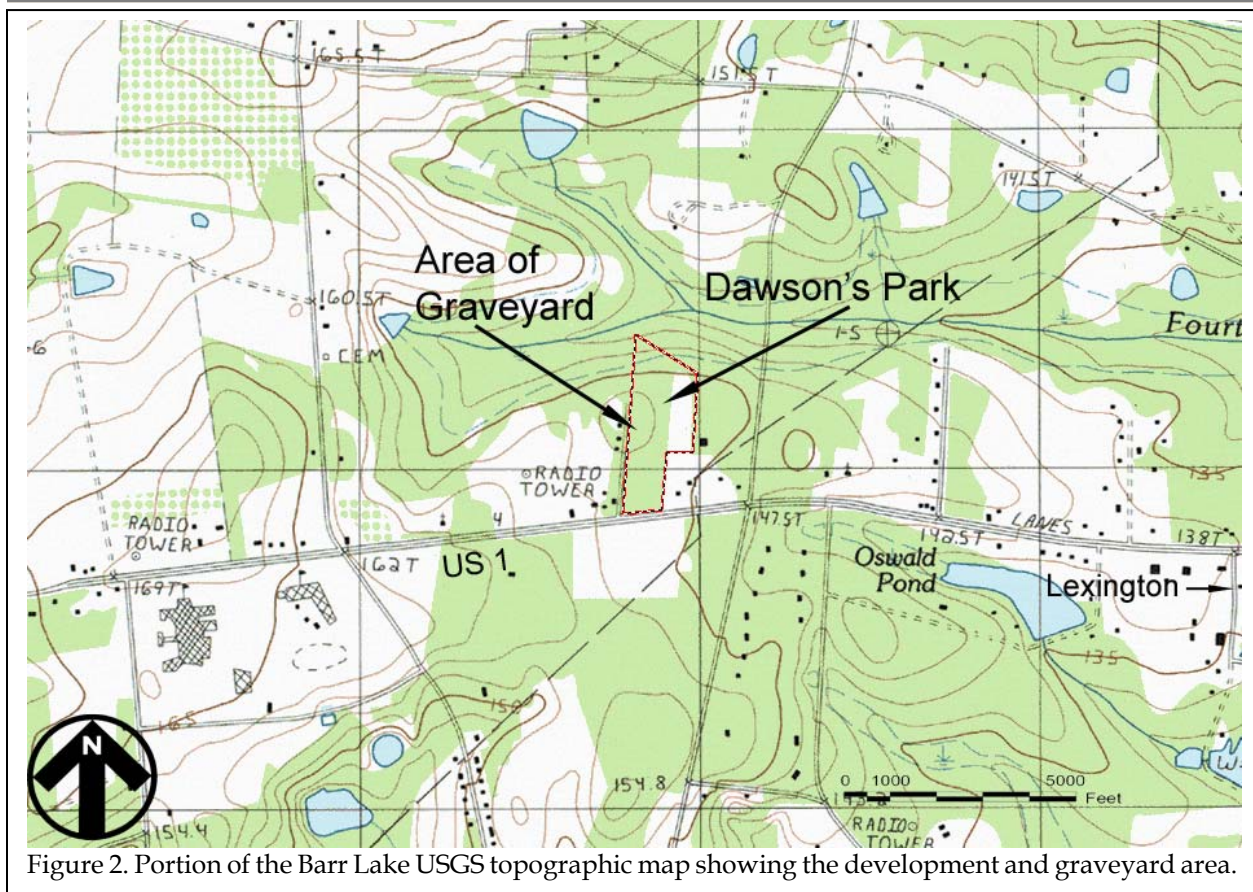


Figure 2. Portion of the Barr Lake USGS topographic map showing the development and graveyard area.

excavation, between lots 153 and 154. No spoil had been screened in this area and at the time of our visit there was no clear evidence of a burial shaft or other remains.

Inspections did, however, reveal scattered human remains on the surface from Dawson's Park Drive eastward for about 150 feet to Elizabeth Drive. Remains did not appear to extend northward across Dawson's Drive, but did extend about 300 feet to the south. Initially the area to the west was discounted because of reported clearing, grubbing, and filling. However, additional bone was subsequently found to the west, extending to the fence and property line, about 120 feet. Based on this survey surface remains were thought to be thinly spread over an area perhaps 300 by 400 feet, or about 2.7 acre.

The surface remains were flagged and collected. Those east of Dawson's Drive were numbered sequentially beginning with 1. Those

west of Dawson's Drive were numbered sequentially beginning with 100. The locations were plotted by Mr. Yandle's surveyor for future use.

An initial effort to identify burials used a penetrometer – a device for measuring ground compaction. Five additional potential graves were identified, but in general soils in the area were too heavily compacted from the clearing and grubbing to allow successful identification. These five additional burials were all identified in the immediate vicinity of Burial 1, extending from lot 156 through lot 158.

Subsequently, ground penetrating radar was contracted with GEL Geophysics in Charleston, South Carolina. Their efforts identified anomalies extending throughout the study area and extending northward for about an additional 200 feet. Thus, anomalies have been identified over an area of perhaps 4 acres, with boundaries

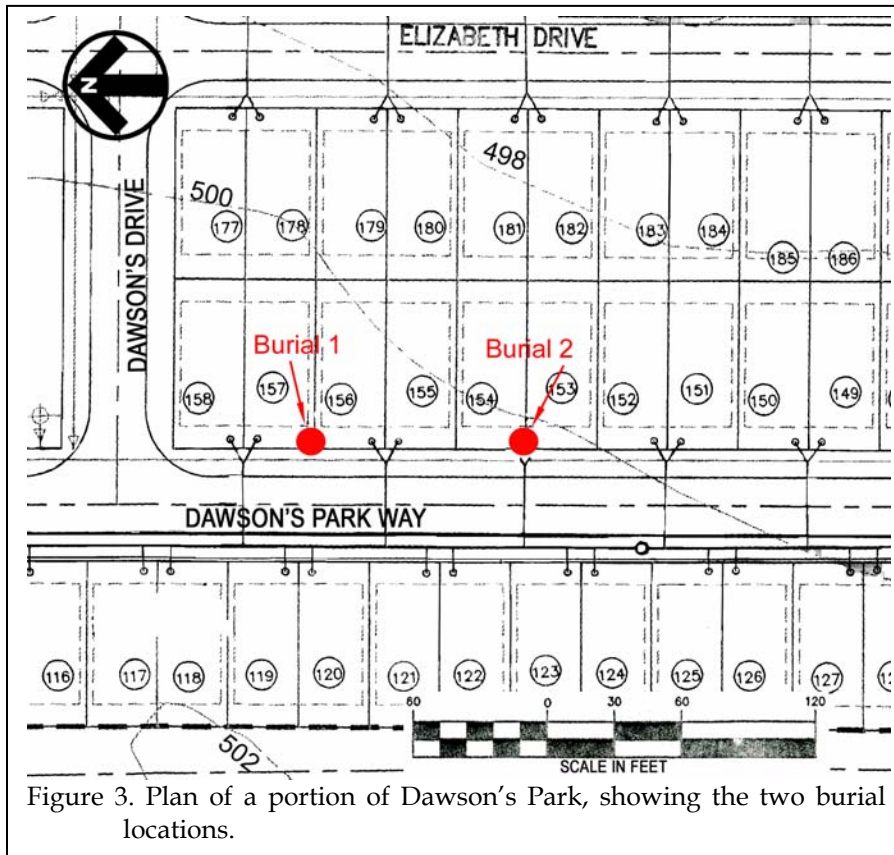


Figure 3. Plan of a portion of Dawson's Park, showing the two burial locations.

poorly defined to the west and south.

It must be noted that anomalies cannot – and should not – be equated with graves. It is not possible to distinguish graves from a variety of other objects in the soil, such as roots or even clay masses. Anomalies vary in strength or intensity -- and these must be ground truthed through excavation (not yet conducted) in order to determine which anomalies represent graves and which represent other materials that are not of significance.

This study, however, reports only on the analysis of the human remains identified from construction activities. This will include the material from the two graves turned over to Chicora by the Lexington County Coroner, as well as the surface remains identified during several field inspections.

Historical Synopsis

Detailed historical research is reported by Trinkley (2007) and this will provide only a brief synopsis of the results.

In 1881 David Drafts, a 51 year old freedman living in the Lexington area, purchased a roughly 62 acre parcel of land (described as 55 acres) from a white farmer, Levi Smith. What is perhaps most amazing about this story is that Drafts, in only 16 years working for wages, was able to save the \$220 (\$4,150 in 2006\$) necessary to purchase the tract.

Drafts lived about 20 more years, dying between 1900 and 1905,

leaving a very large family. His estate was split into seven 8¾ acre parcels and distributed to various children. While a plat of the division was created, it has not been located.

Although it seems reasonable that a large family at that time would need a cemetery, no mention was made of the family burial grounds until 1927 when the family members owning Tract 3 – Green Cortman, Ellen Trapp, and Siller Gardner – sold their 8¾ acres to another African American, Andrew Gates, for \$170 (\$1,980 in 2006\$). That deed reserves to the family a cemetery, estimated to be no larger than ¼ acre. Unfortunately, again no plat of this cemetery was located.

The property again changed hands in 1936, when it was sold by Gates to Vera E. Hendrix (no mention of the cemetery occurs in that deed). Oral history accounts indicate that Vera Hendrix was accepting of the cemetery and

ANALYSIS OF HUMAN SKELETAL REMAINS DISCOVERED BY CONSTRUCTION ACTIVITIES



Figure 4. View of the development tract looking south showing the area of Burial 1 in the foreground and Burial 2 in the background.

allowed burials to continue. She passed the property to her children, Kenneth E. and Seth M. Hendrix in 1956, maintaining a life interest until her death in 1965. Oral history accounts suggest that sometime in the late 1950s or early 1960s, probably when Vera Hendrix was no longer closely associated with the property, one son

may have extended beyond the original boundaries.

By 1959 a road cutting diagonally across the tract is clearly visible. This road is an important landmark in oral history. The bulk of the cemetery is reported to the south of this road,



Figure 5. Central development area, looking northeast from Burial 1.

prohibited any further burials and prevented descendants from maintaining existing graves. Kenneth and Seth Hendrix passed the property to their children and, in 2006, it was sold to N.B.T. of Columbia, Inc.

The cemetery is found on no maps. Aerial imagery from 1943 reveals that an old field on the parcel was in second growth. It seems unlikely that the cemetery extended into that field, although once cultivation was abandoned, burials

although some graves are reported to the north. The road is reported to have cut across Tract 3 (with the graveyard) and into Tract 2, where the house of Ed Drafts was found next to the swamp. Ed Drafts, a son of David Drafts, is reported to have been a root doctor with a large Lexington clientele of both blacks and whites (Rev Carson Wise, personal communication 2007).

The road continues to be clearly

INTRODUCTION

Table 1.
Potentially human remains from east of Dawson’s Park Way

Point	Identification	Notes
1	human radius, left	proximal end largely intact
2	human, skull frag	
3	human, skull frag	
4	human, skull or innominate frag	
5	human, skull or innominate frag	
6	poss. human, rib or long bone	
7	poss. human, longbone	
8	poss. human, longbone	
14	poss. human, innominate or long bone frag	
17	poss. human, innominate	
38	poss. human radius or tibia	distal end
41	poss. human radius or tibia	1, distal end
44	human tibia, left	distal end

the increase. Thus, the estimate of four a year may be too high. Using a more conservative two burials a year would yield perhaps 156 interments.

Regardless, oral history suggests that the bulk of these burials would have occurred from home without benefit of an undertaker. Simple coffins were purchased from Taylor Hardware in Lexington and no commercial markers are

visible in the 1966 and 1977 aerials. Sometime between 1959 and 1966, however, we can see that the tract – including much of what may have been cemetery – was logged. This period of logging is consistent with the period when Seth Hendrix is reported to have forbidden any future burials and prevented descendant access to tend to existing burials (Rev Carson Wise, personal communication 2007).

remembered from the cemetery (Rev. Carson Wise, personal communication 2007).

Excavation of the Remains

The 1966 aerial shows darker vegetation on both sides of the road and the tract’s western limit (although the bulk of the different vegetation appears to be to the north of the road). This may represent what was thought, at that time, to represent the ¼ acre cemetery originally set aside as a result of the 1927 deed.

Little is known about the placement or position of the remains. The incident was first reported when workers encountered a skull as a result of their water line excavation. The Lexington County Sheriff’s Department began screening spoil and the bulk of the post-cranial remains were found in this work. There is no report of any burial shaft being identified or any remains being seen in the walls of the excavation.

Efforts to identify those buried in the cemetery using death certificates has provided limited results with 22 identified (Trinkley 2007:Table 1). This may represent about 4 a year, based on the sampled years of 1920, 1935, and 1940. This is a very small sample, but if we accept it for the sake of discussions, and assume the cemetery was used from 1881 through 1959, then it may contain as many as 312 burials. We do note that burials in the sample increase significantly from one in 1920 to six in 1940. The reason for this increase is not certain, although use by extended family or the results of the depression may explain

While the remains from Burial 1 were being recovered, workers encountered a second skull about 100 feet to the south, in a second area in which they had been allowed to work. No screening of spoil was conducted in this area and, like the area of Burial 1, there is no record of any visible burial shaft or other remains still in situ.

Unfortunately, both holes were backfilled prior to our being able to examine them in detail. In addition, we are not aware of any other remains being identified during earlier phases of construction, which included the excavation and construction of water lines, sewer lines, storm drain lines, and the grading of the roads.

Scattered Remains

As previously discussed, bone remains were identified to the east and west of Dawson's Park Way. All (except those which were obviously animal, based on cut marks or gross anatomy) were flagged, numbered, and collected. The remains were then examined to determine if they were human.

None of the 55 remains west of Dawson's Park Way are human. They represent a range of faunal remains probably relating to the dog pens kept by local individuals on the parcel prior to its development.

Of the 54 remains to the east of Dawson's Park Way, many are also not identifiably human, although 13 were classified as human or possibly human. These are reported in Table 1 below.

Six of these remains are adequately large and sufficiently distinctive to determine they were clearly human. The remaining seven items are

possibly human, but are so fragmented that definitive identification without the use of histological methods is impossible.

There is a growing literature of microscopic bone studies. Mulhern and Ubelaker (2001) suggest that human and nonhuman bone can be distinguished where osteon banding is present. Urbanova and Novotny (2005) provide an equation that combines histometric measurements and grossest morphometric parameter-cortical thickness that reportedly predicts taxonomic classification in 100% of the cases. Hiller and Bell (2007) report that where only Haversian bone tissue is present, it will be impossible to distinguish human from non-human. However, the use of Haversian system diameter and Haversian canal diameter are diagnostic.

All of these techniques, however, require destructive analysis, including thin sectioning, and were beyond the scope of the current study. We have chosen to retain these items as "possibly human" in an abundance of caution.




Figure 6. Examples of human bone identified from the surface of the development tract. A, left radius (point 1); B, left tibia, distal end (point 44); C, skull fragment (point 3); D, skull fragment (point 2).

INTRODUCTION

The human and possible human bone, while scattered, tend to be associated with the area surrounding Burials 1 and 2 and near the development road. They may represent remains from either of the two identified burials or may reflect remains unknowingly encountered during road construction.

ANALYSIS OF BURIALS 1 AND 2

Burial 1

Burial 1 contained cranial fragments and post-cranial fragments of one individual, including 14 vertebrae, 12 ribs, left & right scapulae, right and left clavicles, right and left innominate bones, sacrum, right humerus, left and right radius, right ulna, left femur, and left fibula.

Cranial Bones

The cranium is in fair condition; it is eroded, cracked, warped, and missing some portions post-mortem. In particular, the right temporal area is warped and broken along and above the squamosal suture. All the fragments are present, but misaligned. The frontal area, directly above the nasal area, is eroded and missing, exposing the sinus cavity. Another broken area is the right maxilla, directly below the right orbit. The mastoid processes and the posterior of the occipital condyle, the inferior portion of the nasal bones and the left zygomatic arch are severely eroded. The right zygomatic arch is eroded and partially missing. The styloid processes are missing. The maxillary left first incisor, right first incisor and right second incisor are missing post-mortem. The mandible is not present.

Morphological aspects of the cranium indicate a medium sized skull with sharp orbital borders and small supraorbital ridges, faint temporal muscle lines, low superior nuchal lines and a rounded occipital profile, all generally indicative of a female. There is a mild EOP, medium mastoids, and medium zygomatic arch, which are not gender specific. The only male characteristics of the skull are a large, although not marked, supramastoid crest and large canine teeth. Overall, the skull is morphologically characteristic of a female or gracile male (Burns 1999:154).

Morphological racial attributes include a long narrow vault shape with a medium frontal profile, receding zygomatic bone and arch shape, a medium nasal bridge width and spatulate incisors, all characteristic of European or African descent. The occipital projection is rounded, and there are no wormian or Inca bones present, characteristics of European descent. There is a post bregma sulcus, a lower anterior projection of a medium width face, rectangular shaped orbits with a wide interorbital distance, a low nasal salience, a medium nasal root, a short nasal inferior spine with a nasal sulcus, and the palate arcade shape is rectangular, all characteristic of African descent. Overall, the skull is morphologically characteristic of an individual of African descent (White 2000:377).

Vault, facial and gnathic measurements (Table 2) indicate that the individual was a gracile male of African descent.

Five of ten ectocranial sutures were completely closed, providing an age range of about 40 to 65 years (Buikstra & Ubelaker 1997: 37).

The teeth were totally erupted in the maxilla, for a mean age of greater than 35 years (Buikstra & Ubelaker 1997: 51). Both right incisors and left central incisor are missing post-mortem. The left second incisor is not shoveled, but is worn on the occlusal surface. The left canine occlusal area has been worn away; the right canine occlusal area has been worn away to dentin exposure. The left premolars have some wear on the cusps, while the cusps of the right premolars are worn flat, level with the right canine. The right first molar is missing ante-mortem, with resorbed bone. The left first molar is a small bud, black in color, with no enamel, low occlusal surface, and decay through

Table 2.
Cranial Measurements for Burial 1, in cm

Cranial vault maximum length	18.5
Cranial vault maximum breadth	12.6
Cranial vault maximum height	11.8
Cranial vault frontal breadth	9.8
Upper facial height	76.5
Bizygomatic breadth	129.2
Nasal height	54.0
Nasal breadth	26.0
Basion-nasion	100.0
Basion-brosthion	115.0
Orbit height	33.5
Orbit breadth	42.0

Cranial Index

$$\text{Max. breadth} \times 100 / \text{max. length} = 12.6 \times 100 / 18.5 = 68.1$$

Narrow or long headed

Cranial Module

$$\text{Max. height} + \text{max breadth} + \text{max. height} / 3 = 18.5 + 12.6 + 11.8 / 3 = 42.1 / 3 = 14.0$$

Length - Height

$$\text{Max. height} \times 100 / \text{max. length} = 11.8 \times 100 / 18.5 = 63.8$$

Low skull

Breadth - Height

$$\text{Max. height} \times 100 / \text{max. breadth} = 11.8 \times 100 / 12.6 = 93.7$$

Average skull height

Frontoparietal

$$\text{Min. frontal} \times 100 / \text{max. breadth} = 980 / 12.6 = 77.8$$

Broad

Upper Facial Index

$$\text{Upper height} \times 100 / \text{bizygomatic breadth} = 7650 / 129.2 = 59.2$$

Slender or narrow face

Nasal Index

$$\text{Nasal breadth} \times 100 / \text{nasal height} = 2600 / 54.0 = 48.1$$

Average or medium nasal aperture

Gnathic Index

$$\text{Basion-prosthion} \times 100 / \text{basion-nasion} = 11500 / 100 = 115$$

Prognathic or projecting

Orbital Index

$$\text{Orbit height} \times 100 / \text{orbit breadth} = 3350.0 / 42.0 = 79.8$$

Wide orbits

erupted, and have four cusps, with wear on one cusp of each molar.

All enamel on the teeth has a yellowish cast. There is brown staining on all buccal, lingual and labial areas of the teeth, with the staining darkest on the lingual surface of the second left premolar and left second and third molars. This type of staining is frequently the result of smoking tobacco.

Calculus is evident on the right second molar, and both third molars. Caries are located on the mesial surface of the left second incisor, mesial surface of the first left premolar, and mesial surface of left second premolar. The upper portion of the left canine root and the right second molar are exposed through the bone of the maxilla, indicating abscesses.

Overall, the teeth indicate decay as well as a great deal of wear. There is more wear on the right side, indicating that the individual preferred the use of the right side for chewing, probably because of the decay on the left side.

Post-Cranial Bones

The sacrum, and left and right innominate were present. The sacrum is complete, consisting of five segments, fused, but with evidence of fusing process on the anterior portion. It is in good condition, except for post-mortem erosion of the posterior and anterior raised areas.

the dentin and into the root. There is porous bone around it, and most of the tooth may have been below the gum line ante-mortem. The left second molar has three cusps, with wear on one, while on the right second molar the cusps have been totally worn away, exposing the dentin, with the enamel rim complete around the tooth, indicative of excessive wear. The third molars are present and

<p>Table 3. Sex Estimation, Left Innominate (Bass 1995:200)</p> <p>Ischium-Pubis Index = pubis length x 100/ischium length</p> <p style="text-align: center;">$10584/122.49 = 86.41$</p> <p>African American Male 71-88 African American Female 84-106</p>

Morphological sex characteristics found on the sacrum include a medium size with a mild curvature, determinate of neither male nor female, while the centrum/ala measurement was 125.1/121.0, or a ratio of greater than 1/3, indicating a male individual (Bass 1995:113).

The right innominate was broken into two fragments, warped and eroded post-mortem. There is only a partial acetabulum, and no ischium or symphysis pubis. The left innominate was also broken into two fragments, and eroded post-mortem. Missing fragments include portions of the iliac crest and the anterior inferior iliac spine.

Morphological sex characteristics found on the innominate included a vertical ilium, a narrow pelvic inlet, D-shaped pubic symphysis, narrow sciatic notch, a convex subpubic concavity, and an absent ventral arc, all characteristics of a male individual. While there is a preauricular sulcus on the left innominate, this is not a definitive indication of a female individual (Bass 1995:210). The Ischium-Pubis Index (Table 3) is 86.4, or statistically indeterminate (Bass 1995: 200).

The modal changes of the left innominate auricular surface indicate Phase 7, "dense irregular surface of rugged topography and moderate to marked activity in periauricular areas." Phase 7 represents an estimated age of 50 to 60 years (White 2000: 359).

Only 14 vertebrae were recovered. Of the cervical vertebrae, only C-5, C-6, and C-7 were present; none had a complete spinous process or transverse process, having broken off or eroded

post-mortem. Of the thoracic vertebrae, only T-1, T-2, T-3, T-4, T-5 and T-12 were present. T-2 and T-12 were missing the posterior half of the body, as well as the spinous process and the transverse process, post-mortem. All other thoracic vertebrae were missing their spinous processes and transverse processes, post-mortem. All five of the lumbar vertebrae were present, and were missing their spinous processes and transverse processes post-mortem as well. All vertebrae exhibit porosity, marginal lipping and osteophyte development; some also exhibit Schmorl's nodes, or erosive lesions. The lumbar vertebrae exhibit the most significant amount of lipping and spurring. These are all characteristics of primary osteoarthritis, a degenerative bone disease resulting from age, mechanical stress, or genetic predisposition (White 2000:398). These bone alterations are the result of years of changes to the cartilage between the vertebrae; the more the bone changes, the more discomfort the individual will experience (Ortner 1985:419).

No sternum was recovered from this individual; nine left ribs and seven right ribs were recovered. All ribs were fragmented and missing sternal ends, which appear to have been eroded and spalled away. As a result, no aging based on sternal-end ossification was possible.

Both the left and right scapula were recovered; however, they were incomplete and in poor condition, each missing the body, as well as the majority of the spine and axillary border. The glenoid cavity was present in each, yielding length measurements of 42.3mm for the left scapula, and 44.0mm for the right scapula. Measurements above 37mm indicate a male individual (Bass 1995: 129). There is complete union of the coracoid epiphyses, indicating an individual of over 25 years of age (Bass 1995:126)

Both clavicles were recovered, and were complete, except for minor erosion on the left clavicle anterior body. There was complete union of the epiphyses, indicating an individual of over

21 years in age (Bass 1995:136). The length and circumference of the right clavicle were 160.0mm and 46.0mm. The length and circumference of the left clavicle were 154.5mm and 500mm.

The left humerus was recovered and complete, except for a minor amount of post-mortem erosion. Measurements taken are noted in Table 4; the stature formula for the humerus indicates that this individual had a probable height of between 5'10" and 6'2" (Burns 1999:155). The diameter of the humerus head is 48.0mm, indicative of a male individual (Bass 1995:156). All epiphyses are united, indicating an age of over 23 years (Bass 1995:17). Only a portion of the shaft of the right humerus was recovered, with a maximum length of 165.5mm. The shaft fragment is in very poor condition, eroded, bleached, warped, and split; there is a green discoloration, on the lateral portion of the shaft, distal to the

The left radius was recovered, and although complete, is eroded and splitting. All epiphyses are united, indicating an age of over 19 years (Bass 1995: 168). Measurements are noted in Table 4; the stature formula for the radius indicates that the individual's height range is 5'8" to 6'0" (Burns 1999: 156). The radius head diameter is 24.1mm. The right radius was incomplete, with only 242.0mm of the distal portion recovered.

Only the proximal half of the right ulna was recovered; no measurements were taken. The left ulna was not recovered.

The left femur was recovered, but is incomplete, broken, split and eroded. It has a maximum length of 131.0mm; present are the tibial articular surface, intercondylar fossa, and a portion of the patella articular surface. No other measurements were taken.

The left fibula was also recovered, but is also incomplete, broken, split and eroded. It has a maximum length of 178.5mm; no other measurements were taken.

Other Artifactual Remains

Nails and clothing fragments were also found in Burial 1. The nails consisted of four iron nail fragments, with the impression of wood in the iron oxide residue; these were probably coffin nails. No measures are possible.

Clothing items included shoe fragments, suspender clasp fragments, and buttons.

The shoe fragments were three fragments of leather, with one, two, and three brass grommets respectively, indicative of lace up shoes or boots. There were two iron fragments of a suspender clasp,

nutrient foramen, possibly from exposure to a brass object in the grave.

Table 4. Stature Estimates Based on Humerus and Radius (White 2000:372)	
Left Humerus (measurements in cm)	
Max. length	373.0
Max. diameter, midshaft	25.9
Min. diameter, midshaft	21.2
Max. diameter of head	48.0
Least circumference of shaft	7.5
Vertical diameter of humerus head	44.6
Transverse diameter of humerus head	47.8
Biepicondylar width	58.9
Articular width	34.2
Stature formula, humerus [93.26 x 37.30 + 62.10] ± 4.43 = 179.3 → 188.1cm or 5'11" → 6'2"	
Left Radius (measurements in cm)	
Max. length	278.0
Head diameter	24.1
Stature formula, radius [93.42 x 27.80 + 81.56] ± 4.30 = 171.0 → 179.6cm or 5.7 → 5'11"	

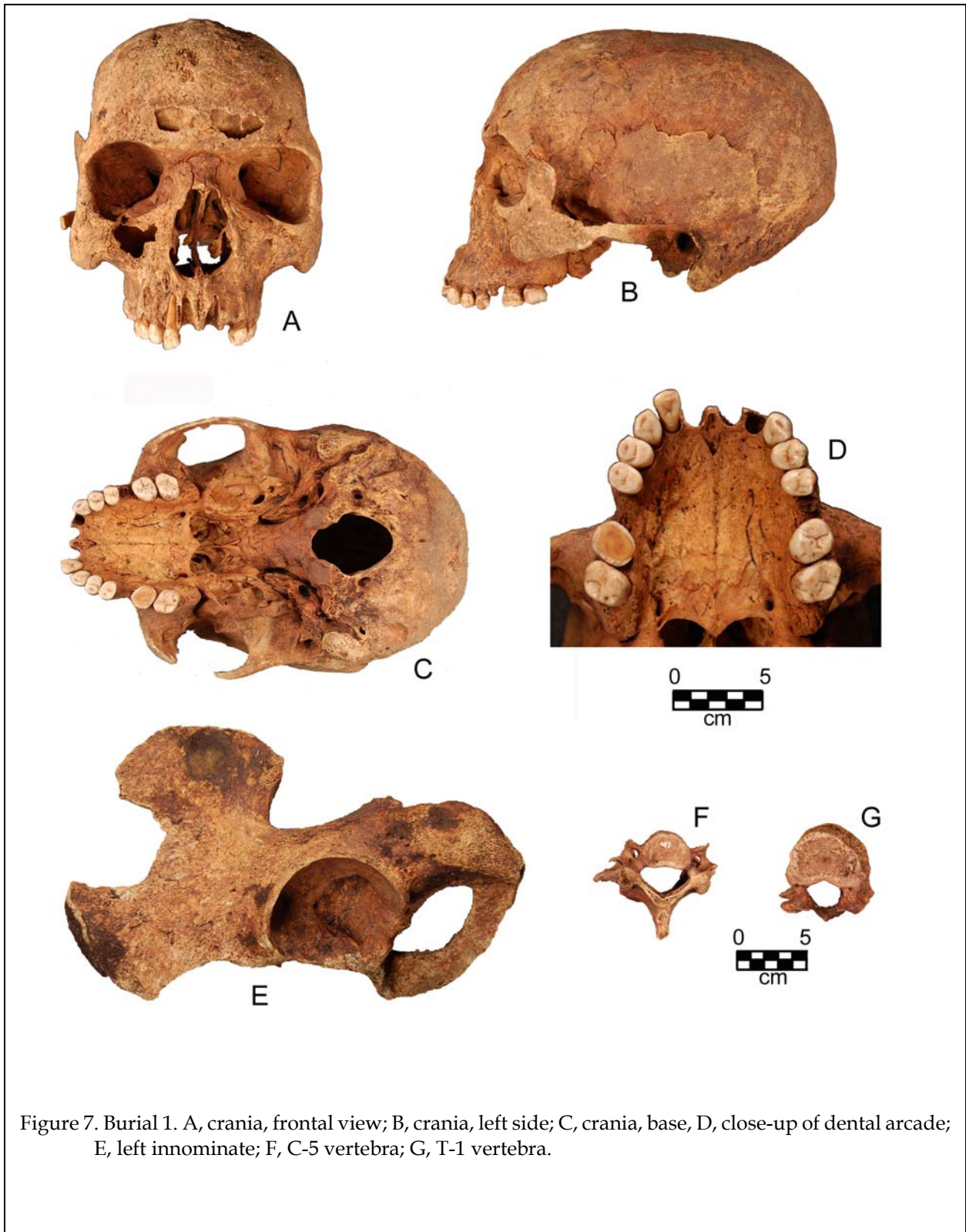


Figure 7. Burial 1. A, crania, frontal view; B, crania, left side; C, crania, base, D, close-up of dental arcade; E, left innominate; F, C-5 vertebra; G, T-1 vertebra.

Table 5.
Cranial Measurements for Burial 2, in cm.

Cranial vault maximum breadth	34.0
Cranial vault maximum height	38.0
Nasal height	44.3
Nasal breadth	28.2
Nasal Index	
Nasal breadth x 100/nasal height = 2800/44.3 = 63.7	
Broad or wide nasal aperture	
Orbital Index	
Orbit height x 100/orbit breadth = 3800.0/34.0 = 118.8	
Narrow orbits	

one hook, and one sliding clasp, both with small pieces of textile imbedded in the iron oxide residue. There were eight buttons: one white porcelain, two-hole button, with a cross-hatched pattern on the front, probably from a shirt; two hard rubber buttons, four-hole, probably from a jacket or coat; and five brass machine-stamped, four-hole buttons. Each of these brass buttons has pieces of textile imbedded in the corroded brass, as well as thread in the holes, from attaching the buttons to the clothing, probably a jacket.

Conclusions

The individual in Burial 1 appears to be an African-American male, 40-65 years of age, with a height of 5'8" to 6'2". The taller height would not be unusual for a member of the Drafts family, as they are known, even today, for heights of over 6 feet (Rev. Carson Wise, personal communication 2007). Although there was significant tooth wear and decay, as well as degenerative arthritis in the spine, no other illness or trauma could be detected in the remains.

The individual appears to have been clothed for burial in a simple wooden coffin, perhaps lacking other hardware.

Burial 2

Burial 2 contained cranial and post-cranial fragments of one individual, including eight skull fragments and one vertebra.

Cranial Bones

The cranium is in poor condition; it is eroded, cracked, warped, broken into eight fragments, and missing some portions post-mortem. In particular, the occipital bone and mandible are missing. The remaining fragments are too warped to reattach for measurements and are misaligned. The mastoid processes are eroded. The right zygomatic arches are missing. The styloid processes are missing. The maxillary left first and second incisors are missing post-mortem.

Morphological aspects of the cranium indicate a medium sized skull with sharp orbital borders, small supraorbital ridges, faint temporal muscle lines, small mastoid processes, low superior nuchal lines, and small canines, all generally indicative of a female. There are no male characteristics noted on the skull bones present. Overall, the skull is morphologically characteristic of a female or gracile male (Burns 1999:154).

Morphological racial attributes include narrow eye orbits and a triangular palate arcade shape, both characteristic of European descent. The occipital projection is rounded, there is no nasal sill, the nasal aperture is broad or wide, and the lower face exhibits prognathism, characteristics of African descent. Overall, the skull is characteristic of an individual of African and European descent (White 2000:377).

Measurements taken of the cranial bones and morphological characteristics indicate that the individual in Burial 2 was a female of European and African descent (Table 5).

All ten ectocranial sutures were somewhat closed, providing an age range of about 30 to 65 years (Buikstra & Ubelaker 1997:370).

The teeth were totally erupted in the

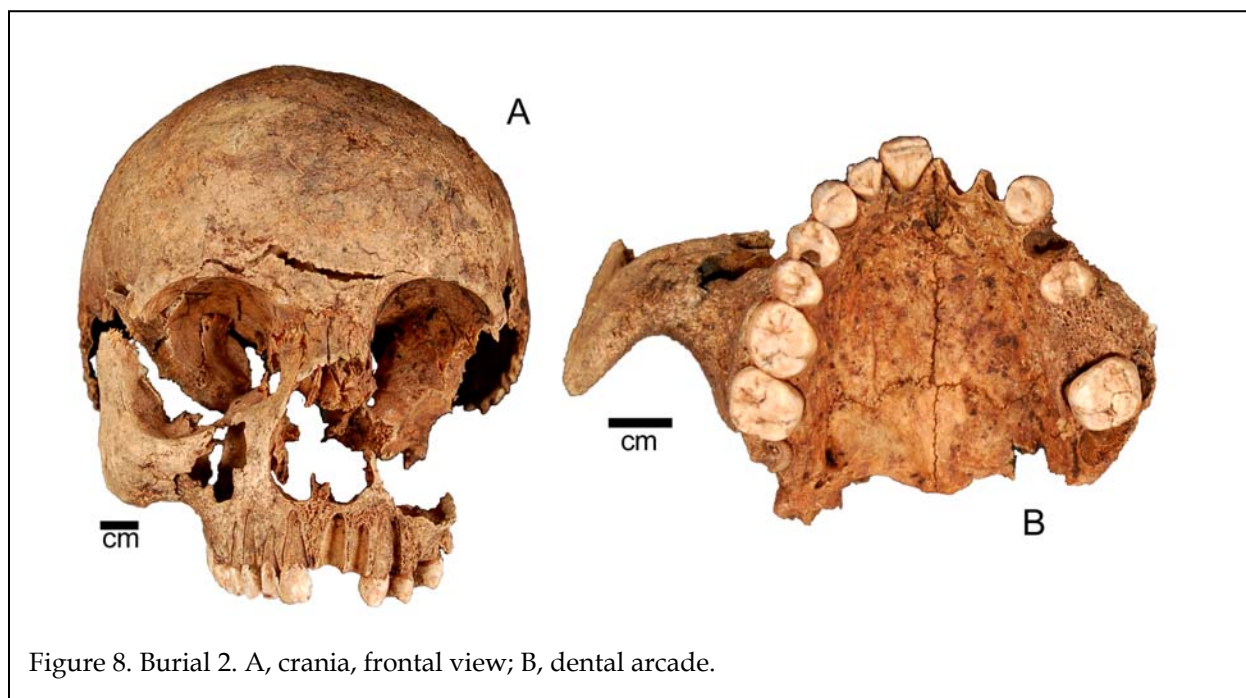


Figure 8. Burial 2. A, crania, frontal view; B, dental arcade.

maxilla, for a mean age of greater than 35 years (Buikstra & Ubelaker 1997:51). Both left incisors are missing post-mortem. The right incisors are shoveled, but worn on the occlusal surface. The right and left canine occlusal areas have been worn away to dentin exposure. The right premolars have some wear on the cusps, with the first premolar exhibiting a large caries through the dentin on the occlusal and distal surface. The cusps of the left first premolar have a small amount of wear; the left second premolar has very little occlusal wear and there is a large caries on the distal surface, into the dentin. The right first and second molars have four cusps, slightly worn, and calculus on the lingual and buccal surfaces. The left first molar is missing ante-mortem, with resorbed bone. The left second molar has four cusps, all worn, with some calculus on the lingual surface. The third molars are present and erupted; the right third molar has lost all enamel and dentin, with the root area exposed. The bone surrounding it is porous and it appears that what remains of the tooth was below the gum line. The left third molar has three cusps, with only one cusp slightly worn.

All enamel on the teeth has a yellowish

cast. Due to erosion of the anterior portion of the maxilla, it is difficult to note any abscessed areas.

Overall, the teeth indicate wear as well as some serious decay on two teeth. In addition, one molar was missing ante-mortem, with another molar probably in the process of being lost due to massive decay.

Post-Cranial Bones

The only post-cranial bone recovered is a fragment of the second cervical vertebra, or axis. The spinous process is missing, but the body exhibits porosity, with marginal lipping and osteophyte development, indicative of primary osteoarthritis, a degenerative bone disease resulting from age, mechanical stress, or genetic predisposition (White 2000:398).

Conclusions

The individual in Burial 2 appears to be a female of mixed African and European descent, 30-65 years of age. This is not inconsistent with the Drafts family history, where inter-racial unions were known (Rev. Carson Wise, personal

communication 2007). Although there was significant tooth wear and decay, as well as degenerative arthritis in the spine, no other illness or trauma could be detected in the remains.

CONCLUSIONS AND RECOMMENDATIONS

"Mortui Vivis Praecipant." It means, "Let the dead teach the living" and is the motto of forensic pathologists and anthropologists alike. In the examination of death it is possible to learn about life and to better understand the history of those who came before us. We honor our ancestors by allowing them to speak to us and tell us their stories – stories that would otherwise never be heard.

African Americans represented 58% of South Carolina's population in 1860 and 51% even as late as 1920. African Americans in Lexington County, however, were always a minority, representing less than a third of the population in 1930.

Yet in osteological data banks, such as the world renowned Forensic Anthropology Data Bank at the University of Tennessee, African Americans comprise a relatively small (and non-representative) proportion of the materials. Thus, even for modern populations, our understanding of African American populations is far from complete.

While the sample of remains from the Drafts Cemetery is very small and little can be made of the results of this study, it is nevertheless of critical importance. It is, for example, the only sample of an interior South Carolina African American population. There are several studies of African American groups from the low country and much of that work is presented by the review of Blakey (2001); but for the midlands we have had no opportunity to examine the health, diet, and evidence of disease presented by skeletal remains.

The two burials (one represented only a single vertebra and partial crania) provide a view that is perhaps contrary to conventional wisdom. The two individuals, in so far as can be

determined, were remarkably healthy. There is no hypoplasia – indicating nutritional or other health related stress during childhood – in the teeth of either individual. There is no evidence of anemia, syphilis, tuberculosis, or other long-lasting infection. There is no significant degenerative arthritis in any of the vertebra of Burial 1. There is no evidence of broken bones or other pathologies.

The limited research suggests that many individuals in the family operated small subsistence farms. This departure from traditional tenancy may be partially responsible for a better diet – and thus better overall health as reflected in the skeletal remains.

The remains of Burial 2 are characteristic of an individual of African and European descent. Burial 1 presents a stature that is relatively tall. Both support oral history accounts of the extended Drafts family.

The non-skeletal remains associated with Burial 1 are consistent with an inexpensive wood coffin burial lacking coffin hardware. The individual was buried in leather shoes, pants, shirt, and coat. This gives us the impression of a home burial – again consistent with the oral history.

If it becomes necessary to move burials associated with the Drafts cemetery, there is an unprecedented opportunity to learn about this small African American community in Lexington County.

Metric and non-metric studies – such as those conducted for this study – provide baseline information on the age, sex, stature, and general appearance of individuals, as well as information on health and disease. These studies are entirely non-destructive, causing no damage or

deterioration to the remains. Through this process not only can we increase our knowledge of African American lifeways, but the family members today can learn about their ancestors. Information derived from the study may even allow possible identification of some individuals with unique attributes.

There is the possibility that health studies can be further advanced through the extraction of noncollagenous proteins, some of which are synthesized in response to infections. Newly developed techniques for the extraction of these proteins from bone, requiring samples of only a gram, may contribute to our understanding of specific diseases.

Chemical studies allow even greater refinement and precision regarding dietary study. For example carbon and nitrogen isotopes can identify diets rich in corn (using carbon isotopes) or legumes and non-legumes (using nitrogen isotopes). Trace mineral studies can provide additional clues concerning diet.

Using polymerase chain reaction (PCR) it is possible to examine nuclear and mitochondrial DNA. This allows relationships to be established at familial, regional, and supraregional levels. Such an approach would not only be useful to researchers, but would help classify remains that must be moved.

One need only examine the 800+ pages generated by the examination of the 419 individuals recovered from the New York African American Burial Ground in New York City to fully appreciate the potential of skeletal remains to teach the living (Blakey and Rankin-Hill 2004). The examination of these documents also testifies that such work can be accomplished in a manner that is ethical and sensitive to community standards and concerns.

With the extraordinary population available the researchers provide exemplary research on issues ranging from odontological indicators of disease, diet, and nutrition to adult and sub-adult mortality to an analysis of stress

markers.

While we don't intend to suggest that all studies will have either the sample or funding to achieve such success, it is critical that each body be allowed to make its contribution to knowledge – that each individual be allowed to contribute his or her story about their life. This can only be accomplished through careful forensic study.

SOURCES CITED

Bass, William M.

- 1995 *Human Osteology: A Laboratory and Field Manual*. Missouri Archaeological Society, Columbia.

White, Tim D.

- 2000 *Human Osteology*. Academic Press, San Diego.

Blakey, Michael L.

- 2001 Bioarchaeology of the African Diaspora in the Americas: Its Origins and Scope. *Annual Review of Anthropology* 30:387-422.

Blakey, Michael L. and Lesley M. Rankin-Hill, editors

- 2004 *Skeletal Biology Final Report, African American Burial Ground Project*. Howard University, Washington, D.C.

Buikstra, Jane E. and Douglas H. Ubelaker

- 1995 *Standards for Data Collection from Human Skeletal Remains*. Research Series 44. Arkansas Archeological Survey, Fayetteville.

Burns, Karen Ramey

- 1999 *Forensic Anthropology Training Manual*. Prentice Hall, Upper Saddle River, New Jersey.

Ortner, Donald J. and Walter G.J. Putschar

- 1985 *Identification of Pathological Conditions in Human Skeletal Remains*. Smithsonian Institution Press, Washington, D.C.

Trinkley, Michael

- 2007 *Historical Research on Drafts Graveyard, Lexington County, South Carolina*. Research Contribution 474. Chicora Foundation, Inc., Columbia.

**Archaeological
Investigations**

Historical Research

Preservation

Education

Interpretation

Heritage Marketing

**Museum Support
Programs**



Chicora Foundation, Inc.
PO Box 8664 • 861 Arbutus Drive
Columbia, SC 29202-8664
Tel: 803-787-6910
Fax: 803-787-6910
www.chicora.org